

Ankyloglossia: Assessment, Incidence, and Effect of Frenuloplasty on the Breastfeeding Dyad

Jeanne L. Ballard, MD*; Christine E. Auer, RN, IBCLC§; and Jane C. Khoury, MS‡

ABSTRACT. *Objective.* Ankyloglossia in breastfeeding infants can cause ineffective latch, inadequate milk transfer, and maternal nipple pain, resulting in untimely weaning. The question of whether the performance of a frenuloplasty benefits the breastfeeding dyad in such a situation remains controversial. We wished to 1) define significant ankyloglossia, 2) determine the incidence in breastfeeding infants, and 3) measure the effectiveness of the frenuloplasty procedure with respect to solving specific breastfeeding problems in mother–infant dyads who served as their own controls.

Methods. We examined 2763 breastfeeding inpatient infants and 273 outpatient infants with breastfeeding problems for possible ankyloglossia and assessed each infant with ankyloglossia, using the Hazelbaker Assessment Tool for Lingual Frenulum Function. We then observed each dyad while breastfeeding. When latch problems were seen, we asked the mother to describe the sensation and quality of the suck at the breast. When pain was described, we asked the mother to grade her pain on a scale of 1 to 10. When lingual function was impaired, we discussed the frenuloplasty procedure with the parent(s) and obtained informed consent. After the procedure, the infants were returned to their mothers for breastfeeding. Infant latch and maternal nipple pain were reassessed at this time.

Results. Ankyloglossia was diagnosed in 88 (3.2%) of the inpatients and in 35 (12.8%) of the outpatients. Mean Hazelbaker scores were similar for the presenting symptoms of poor latch and nipple pain. Median infant age (25th and 75th percentiles) at presentation was lower for poor latch than for nipple pain: 1.2 days (0.7, 2.0) versus 2.0 days (1.0, 12.0), respectively. All frenuloplasties were performed without incident. Latch improved in all cases, and maternal pain levels fell significantly after the procedure: 6.9 ± 2.31 down to 1.2 ± 1.52 .

Conclusion. Ankyloglossia is a relatively common finding in the newborn population and represents a significant proportion of breastfeeding problems. Poor infant latch and maternal nipple pain are frequently associated with this finding. Careful assessment of the lingual function, followed by frenuloplasty when indicated, seems to be a successful approach to the facilitation of breastfeeding in the presence of significant ankyloglossia. *Pediatrics* 2002;110(5). URL: <http://www.pediatrics.org/cgi/content/full/110/5/e63>

[pediatrics.org/cgi/content/full/110/5/e63](http://www.pediatrics.org/cgi/content/full/110/5/e63); *ankyloglossia, tongue-tie, nipple pain, poor latch, failure to thrive, problem breastfeeding, frenuloplasty/frenotomy.*

ABBREVIATION. SD, standard deviation.

Ankyloglossia in the newborn or young infant is a subject of ongoing controversy among various professional individuals as well as specialty groups.¹ The controversy involves not only the management but also the definition of this anomaly. A tight lingual frenulum is considered a minor malformation by some investigators.^{2,3} It is also found to be part of certain malformation syndromes.^{4–10} Although a high-arched palate and recessed chin may be seen as part of the craniofacial constellation,¹¹ most commonly a tight lingual frenulum is seen as an isolated finding in an otherwise normal infant. Messner and Lalakea¹ conducted a survey of otolaryngologists, pediatricians, speech pathologists, and lactation consultants to determine their approaches to ankyloglossia and their beliefs regarding its association with feeding, speech, and social/mechanical problems. Survey results demonstrated significant differences within and among these professional groups, with pediatricians being the least likely to recommend surgery. Wright¹² concluded from a retrospective study that there is no place for neonatal frenulotomy. Sanchez-Ruiz et al,¹³ however, reported problems with deglutition and dentition in older children with uncorrected lingual frenula. Other authors, such as Hasan,¹⁴ reported that tongue-tie was a cause of lower incisor deformity. Williams and Waldron¹⁵ reported that dental specialists are frequently confronted with the dilemma of relating the tight frenulum to certain types of oral-motor dysfunction. Ewart¹⁶ reported an adult male with tongue-tie, gingival recession, and a speech impediment requiring surgery. Several investigators have alluded to ankyloglossia as being problematic for breastfeeding dyads and have proposed surgical correction in such situations.^{17–25}

The purpose of this study was to look at the incidence, gender, and age at presentation and the impact of significant ankyloglossia in our population of breastfeeding infants. We defined the severity of the condition by using a quantitative tool, the Hazelbaker Lingual Assessment Tool,²⁶ scoring both the function and the appearance of the tongue. We related lingual function and appearance scores to each other and to the quality of the infant's latch and

From the *Department of Pediatrics, Cincinnati Children's Hospital, ‡Division of Epidemiology and Biostatistics, Department of Environmental Health, University of Cincinnati, Cincinnati, Ohio; and the §Health Alliance of Greater Cincinnati, Cincinnati, Ohio.

This article was presented in part at the Pediatric Academic Societies Meeting; Boston, MA; May 13, 2000.

Received for publication Apr 10, 2002; accepted Jul 11, 2002.

Reprint requests to (J.L.B.) University of Cincinnati College of Medicine, 231 Albert Sabin Way, Cincinnati, OH 45267-0541. E-mail: jeanne.ballard@uc.edu
PEDIATRICS (ISSN 0031 4005). Copyright © 2002 by the American Academy of Pediatrics.

degree of maternal nipple pain during breastfeedings. Finally, we assessed the effect of frenuloplasty on the infant's latch and the mother's nipple pain.

METHODS

Between January 1, 1998, and June 30, 2001, we examined 2763 term, inpatient breastfeeding infants and 273 outpatient breastfeeding infants for evidence of ankyloglossia, ie, a short or tight lingual frenulum. Specifically, in all breastfeeding inpatients, on initial physical examination the investigator (J.L.B.) looked for a membrane attached between the tip and middle portion of the inferior aspect of the tongue, extending to the anterior floor of the mouth, just beneath or directly onto the posterior alveolar ridge (Fig 1). The outpatients were examined and diagnosed by J.L.B. when they presented to our lactation center with a variety of breastfeeding problems. To quantify the function and appearance of the tongue of each infant with ankyloglossia, we used the assessment tool developed by Hazelbaker²⁶ (Table 1). Significant ankyloglossia was defined as a function score of 11 or less out of a possible 14, in the presence of an appearance score of 8 or less out of a possible 10. When we identified significant ankyloglossia, we proceeded to assess the dyad for infant latch and maternal nipple pain.

We observed the infant for frustration at the breast, or inability to sustain a good latch. If the infant latched onto the breast, then we assessed the quality of the latch by asking the mother to describe the sucking sensation as either gumming or massaging. Latch was not measured quantitatively. Next, we asked the

mother whether she was experiencing any nipple pain or discomfort while the infant was nursing at the breast. When pain was present, we quantified the degree of maternal nipple pain on an analog scale of 1 to 10, with 1 representing extremely mild discomfort and 10 representing severe or intolerable pain. When appropriate, we offered and obtained informed consent to have a frenuloplasty performed on the infant. After the procedure, we returned the infant to the mother to be breastfed. At this time, we reassessed the quality of the infant's latch and the degree of maternal nipple pain. Mothers were asked to describe the latch in their own words, comparing it with the latch before frenuloplasty. Pain levels were obtained after approximately 1 minute of latch on. Inpatients were followed for additional breastfeeding progress until discharge from the hospital. Telephone contact was made routinely with each of the outpatients approximately 3 days after the procedure to ensure successful breastfeeding. This is standard practice for all patients seen in our lactation center. There were no complications related to the procedure.

Assessment Tool for Lingual Frenulum Function

The Hazelbaker score was calculated after scoring the appearance and function items (Table 1) using the following method²⁶: The appearance of the tongue when lifted is determined by inspecting the anterior edge of the tongue as the infant cries or tries to lift or extend the tongue. The elasticity of the frenulum is determined by palpating the frenulum for elasticity while lifting the infant's tongue. The length of the lingual frenulum is determined by noting its approximate length in centimeters as the tongue is lifted. Attachment of the frenulum to the tongue is determined by noting its origin on the inferior aspect of the tongue. It should be approximately 1 cm posterior to the tip. The attachment of the lingual frenulum to the inferior alveolar ridge is determined by noting the location of the anterior attachment of the frenulum. It should insert proximal to or into the genioglossus muscle on the floor of the mouth.

Lateralization is measured by eliciting the transverse tongue reflex by tracing the lower gum ridge and brushing the lateral edge of the tongue with the examiner's finger. Lift of the tongue is noted when the finger is removed from the infant's mouth. If the infant cries, then the tongue tip should lift to mid-mouth without jaw closure. Extension of the tongue is measured by eliciting the tongue extrusion reflex by brushing the lower lip downward toward the chin. Spread of anterior tongue is determined by first eliciting a rooting reflex, just before cupping, by tickling the upper and lower lips and looking for even thinning of the anterior tongue. Cupping is a measure of the degree to which the tongue hugs the finger as the infant sucks on it. Peristalsis is a backward, wave-like motion of the tongue during sucking that should originate at the tip of the tongue and is felt with the back of the examiner's finger. Snapback is heard as a clucking sound when the tethered tongue loses its grasp on the finger or breast when the infant tries to generate negative pressure. Values are assigned as indicated on the score sheet (Table 1).

Frenuloplasty Procedure

In children older than 4 months, anesthesia is usually required because of the infant's strength and awareness. In early infancy, however, the procedure may be accomplished without anesthesia and with minimal discomfort to the infant. The infant is placed supine with the elbows held flexed securely close to the face and the assistant's index finger on the chin for stabilization. The tongue is lifted gently with a sterile, grooved retractor so as to expose the frenulum. With sterile iris scissors, the frenulum is divided by approximately 2 to 3 mm at its thinnest portion, between the tongue and the alveolar ridge, into the sulcus just proximal to the genioglossus muscle. Care is taken not to incise any vascular tissue (the base of the tongue, the genioglossus muscle, or the gingival mucosa). There should be minimal blood loss, ie, no more than a drop or 2, collected on sterile gauze. Crying is usually limited to the period that the infant is restrained. Feeding may be resumed immediately and is without apparent infant discomfort. No specific aftercare is required except that breast milk is recommended for at least the next few feedings.

Statistical Analysis

Data were analyzed using SAS (SAS Institute Inc, Cary, NC). Univariate statistics are reported as mean \pm standard deviation

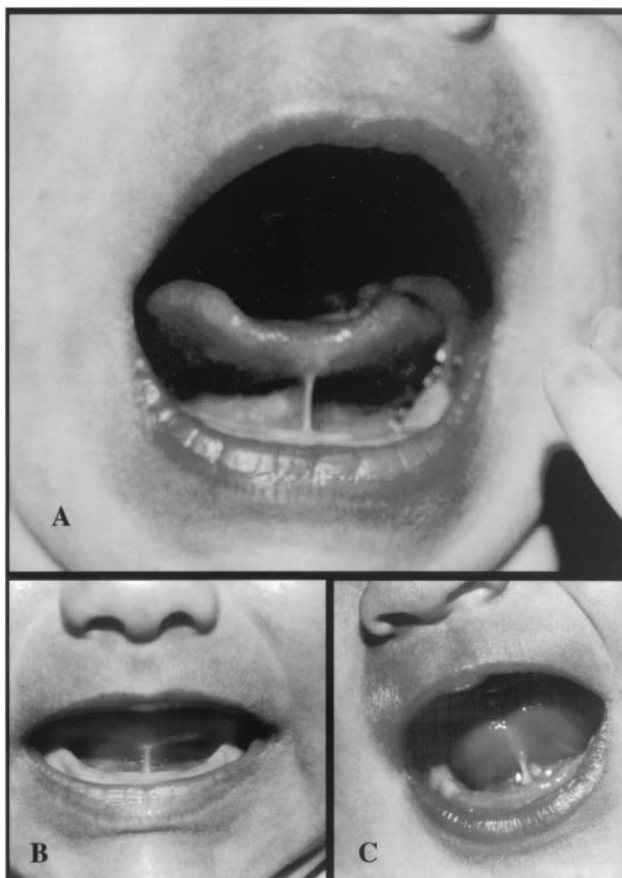


Fig 1. Newborn infants with variations of significant ankyloglossia. A, The lingual frenulum is seen attaching the mid-tongue to the alveolar ridge, allowing only the side edges to lift to the mid-mouth when crying. B, The lingual frenulum connects the tip of the tongue to the alveolar ridge, preventing lift and protrusion of the tongue. C, The lingual frenulum extends from the mid-tongue to just below the alveolar ridge, causing an indentation of the anterior edge, often referred to as a heart-shaped tongue. (Courtesy of Kay Hoover, MED, IBCLC.)

TABLE 1. Hazelbaker Assessment Tool for Lingual Frenulum Function*

Appearance Items	Function Items
Appearance of tongue when lifted 2: Round or square 1: Slight cleft in tip apparent 0: Heart- or V-shaped	Lateralization 2: Complete 1: Body of tongue but not tongue tip 0: None
Elasticity of frenulum 2: Very elastic 1: Moderately elastic 0: Little or no elasticity	Lift of tongue 2: Tip to mid-mouth 1: Only edges to mid-mouth 0: Tip stays at lower alveolar ridge or rises to mid-mouth only with jaw closure
Length of lingual frenulum when tongue lifted 2: >1 cm 1: 1 cm 0: <1 cm	Extention of tongue 2: Tip over lower lip 1: Tip over lower gum only 0: Neither of the above, or anterior or mid-tongue humps
Attachment of lingual frenulum to tongue 2: Posterior to tip 1: At tip 0: Notched tip	Spread of anterior tongue 2: Complete 1: Moderate or partial 0: Little or none
Attachment of lingual frenulum to inferior alveolar ridge 2: Attached to floor of mouth or well below ridge 1: Attached just below ridge 0: Attached at ridge	Cupping 2: Entire edge, firm cup 1: Side edges only, moderate cup 0: Poor or no cup
	Peristalsis 2: Complete, anterior to posterior 1: Partial, originating posterior to tip 0: None or reverse motion
	Snapback 2: None 1: Periodic 0: Frequent or with each suck

Adapted with permission from Hazelbaker.²⁶

* The infant's tongue was assessed using the 5 appearance items and the 7 function items. Significant ankyloglossia was diagnosed when appearance score total was 8 or less and/or function score total was 11 or less.

(SD) or as number and percentage as appropriate. χ^2 and Fisher exact tests were used for preliminary analysis of demographic variables comparing inpatient and outpatient subjects. Analysis was done using 2-sample and paired *t* test and McNemar's test as appropriate. Because of the skewing of the distribution of age in days at presentation, median age and 25th, 75th percentile is reported, and analysis was done using Wilcoxon rank sum. *P* < .05 was considered statistically significant.

RESULTS

Of 3036 breastfeeding infants examined, we identified 127 infants as having significant ankyloglossia. Of these, 4 mothers declined the frenuloplasty, leaving 123 mother–infant dyads that could be reassessed after the procedure. In the total population, the ratio of boys to girls was 1.5:1. Family history was positive for tongue-tie in 26 cases, representing 21% of the infants with ankyloglossia.

We identified 2763 consecutive breastfeeding infants in our hospital at the time of birth. Of these inpatients, 88 were found to have significant ankyloglossia, an incidence of 3.2%. Among these, 56 presented with poor latch and 32 presented with nipple pain. Ankyloglossia accounted for 35 of the 273 dyads (12.8%) with breastfeeding problems seen at our outpatient lactation center. Among these, 14 infants had poor latch and 21 mothers presented with nipple pain. Six outpatient infants presented with failure to thrive: 4 because of poor latch and 2 because maternal nipple pain had precluded adequate milk ejection reflex and, hence, milk transfer. One infant with previously unrecognized anky-

loglossia presented at 4.5 months of age with poor latch and failure to thrive and required hospitalization for fatty infiltration of the liver secondary to prolonged starvation. Another infant, also with failure to thrive, presented at 1 month of age with an infected ulcer of the posterior hard palate. His mother had severely traumatized and infected nipples, which in turn was related to his ankyloglossia. Moderate to severe nipple trauma with or without infection was seen in 21 mothers, recurrent mastitis was seen in 4, and suppressed lactation was seen in 4.

For the 123 infants who were undergoing frenuloplasty, function score mean and SD were 7.9 ± 1.86 . Appearance score, mean, and SD were 4.9 ± 1.81 . There was significant correlation between function and appearance: $r = 0.49$, $P < .001$. Mean function and appearance scores with the presenting complaint of poor latch were 7.8 ± 1.88 and 4.8 ± 1.87 , respectively. With maternal nipple pain, these were 8.0 ± 1.85 and 5.0 ± 1.76 , respectively. The score differences between those who presented with poor latch and those who presented with nipple pain are not statistically significant.

Median (25th, 75th percentile) age at presentation with poor latch was significantly lower than with maternal nipple pain: 1.2 days (0.7, 2.0) versus 2.0 days (1.0, 12.0), respectively ($P = .007$). Specifically, 80% of infants with poor latch presented on day 2 or earlier, whereas 60% of patients with nipple pain

presented after day 2 (Fig 2). Frenuloplasty was followed by improved latch, by maternal report, in all instances in which poor latch was the presenting complaint. Unprompted descriptions included “stronger,” “smoother,” “more natural,” “more like a massage,” “less chewing or gumming,” “more effective,” “getting more milk out,” and so forth. Mean maternal nipple pain levels \pm SD before the frenuloplasty were 6.9 ± 2.31 , whereas immediately after the frenuloplasty, these were 1.2 ± 1.52 ($P < .0001$; Fig 3).

Routine follow-up of the outpatients revealed that 31 of the 35 mothers were breastfeeding more comfortably after the procedure and expressed delight at being able to pursue their original breastfeeding plans. Three patients stopped breastfeeding despite the procedure, and the mother of the 4.5-month-old infant with severe failure to thrive was advised by her pediatrician to feed him primarily formula. The remaining 5 infants with failure to thrive resumed breastfeeding and achieved a normal rate of growth within 3 to 5 days after the procedure.

DISCUSSION

Recent recommendations by the American Academy of Pediatrics state that newborn infants should receive breast milk for the first year of life and well into the second year whenever possible.²⁷ Pediatricians and neonatologists are facing the challenge of facilitating the delivery of breast milk to their newborn infants and of protecting and prolonging the breastfeeding experience for as long as possible. This approach has both short- and long-term benefit for both mother and infant.

Among the most common causes of untimely weaning or early discontinuation of breastfeeding are apparent breast refusal, perceived inadequate milk supply, and introduction of formula supplementation with a subsequent decrease in milk supply.²⁸ Careful inspection may reveal that breast refusal actually represents infant frustration as a result of the infant’s inability to sustain a latch and transfer milk. Inadequate milk supply may be rooted in decreased ejection reflex as a result of maternal nipple pain or in suppressed lactation as a result of the

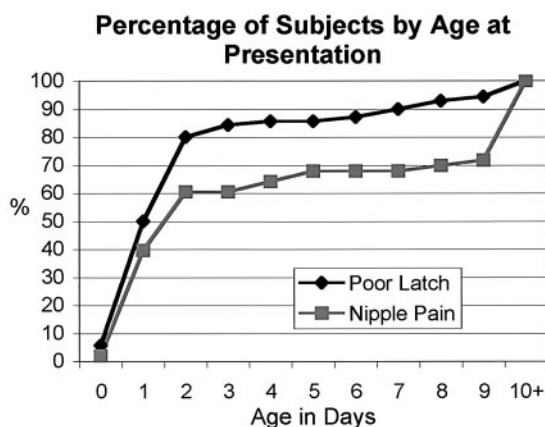


Fig 2. Infants’ ages at presentation. Infants with poor latch presented earlier than did mothers with nipple pain.

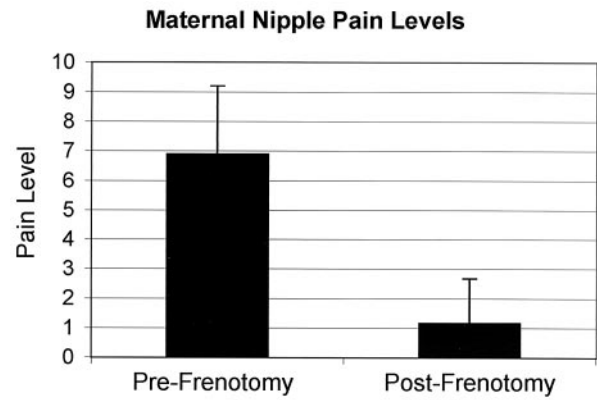


Fig 3. Maternal nipple pain before and after the frenuloplasty. Pain levels decreased significantly after the procedure.

infant’s inability to drain the breast. In our hospital, significant ankyloglossia was diagnosed on the first or second day of life in 3.2% of the entire breastfeeding population seen during the period of study. All of these inpatient dyads exhibited either poor latch or maternal nipple pain while still in the hospital.

Ankyloglossia was responsible for 12.8% of serious outpatient breastfeeding problems referred to our center from other institutions. This is consistent with the 7.4% of damaged nipples attributable to tongue-tie reported by Hazelbaker.²⁶ The outpatients differed from the inpatient population in that their diagnoses included more severe complications, such as yeast; mastitis; damaged, infected nipples; and failure to thrive. They were referred to our lactation center for these complications. Ankyloglossia was diagnosed when seen by us. Once the infants were rendered capable of accomplishing adequate milk transfer and/or maternal nipple pain and breast pathology were relieved, in most cases lactation gradually returned to normal.

Some authors^{21,29,30} have discussed infant ankyloglossia as a cause of breastfeeding problems. Messner et al³¹ reported a slightly higher incidence of ankyloglossia compared with this study, 4.8% of a well-infant population. This difference, although small, may be attributable to individual variability in the definition of ankyloglossia. Our definition was based strictly on the Hazelbaker criteria and included only significant ankyloglossia, whereas Messner’s population included borderline as well as mild cases. The male to female ratio in his population was also slightly higher than in ours, 2.6 to 1. He reported on a comparison between 2 groups of breastfeeding infants, 1 group with ankyloglossia and a control group of normal infants. Of the group with borderline to moderate ankyloglossia, 25% experienced problems, whereas only 3% of the control group experienced difficulties with breastfeeding. We speculate that the relatively low incidence of breastfeeding problems stems from the inclusion of borderline cases and possibly lack of any severe cases of ankyloglossia.

The limitations of this study are that there is neither a control group without frenuloplasty nor any long-term follow-up of duration of breastfeeding.

The high degree of maternal gratification in a vast majority of our mothers, however, combined with their apparent deep commitment to continue breastfeeding despite obstacles, portended that they would achieve their breastfeeding goals. Other limitations are that the Hazelbaker assessment has not been validated in a controlled manner. The tool, however, has undergone content validity evaluation, which is all that is possible with this type of assessment tool. The score does remain in need of formal testing for interrater reliability. We used no quantitative measure of infant latch, relying instead on our observation of the infant's ability to sustain a latch and on the mother's description of the infant's latch quality and subjective sucking sensation.

We believe that inspection of the tongue and its function should be a part of the routine neonatal examination, whether the infant is breastfeeding or not. Thus, parents can be apprised of the presence and severity of ankyloglossia and made aware of potential feeding, speech, and dental problems. Although indiscriminate or immediate clipping of all or most lingual frenula is not universally recommended, there may be specific indications for this intervention.²³ Facilitation of breastfeeding, protection of maternal nipple and breast health, and enhancement of breast milk transfer to the infant are such indications.³¹ Moderate to severe impairment of lingual function as a result of significant ankyloglossia is correctable by the performance of a simple frenuloplasty in early infancy. It may be preventive of breastfeeding casualties and thus be of potential benefit to both infant and mother.³² Given poor infant latch and/or maternal nipple pain, the Hazelbaker Lingual Frenulum Assessment Tool²⁶ can be useful in identifying infants who might benefit from a frenuloplasty. In our inpatient population of breastfeeding infants, 3.8% met these criteria. Ankyloglossia was responsible for 12.8% of severe breastfeeding problems encountered in our outpatient population. Frenuloplasty consistently reduced maternal nipple pain and/or improved infants' ability to latch onto the breast and suck effectively.

CONCLUSION

Ankyloglossia, or tongue-tie, represents a significant proportion of the identified impediments to successful breastfeeding. It is more common in boys than in girls and seems to be genetic in origin. Two major symptoms associated with ankyloglossia in the breastfeeding dyad are poor infant latch and maternal nipple pain, which may be precursors to serious breastfeeding problems. The Hazelbaker tool is a quantitative method of assessment of lingual function and appearance that facilitates the identification of infants with significant ankyloglossia. Milk transfer, infant growth, maternal nipple pain, and breast pathology can improve significantly after frenuloplasty. When performed carefully and with sterile technique, frenuloplasty is a simple, safe, and effective procedure for dyads that have difficulty with breastfeeding secondary to neonatal ankyloglossia. Additional study is needed to elucidate the

definition and significance of this condition with regard to breastfeeding and to clarify the appropriateness and proper timing of the corrective procedure. Randomized, prospective, and long-term follow-up studies are also needed to determine whether the frenuloplasty procedure should be recommended, in selected infants, as an accepted measure to facilitate the continuation of breastfeeding for the entire first year and beyond, as recommended by the American Academy of Pediatrics.²⁷

ACKNOWLEDGMENTS

This work was supported in part by a service grant from the March of Dimes, Ohio Chapter, Cincinnati Children's Hospital Medical Center, and University Hospital, Inc, members of the Health Alliance of Greater Cincinnati.

We thank Alicia Emley for assistance with the illustrations and Dr Lawrence M. Gartner for review of the manuscript.

REFERENCES

- Messner AH, Lalakea ML. Ankyloglossia: controversies in management. *Int J Pediatr Otorhinolaryngol.* 2000;54:123-131
- Rosegger H, Rollett HR, Arrunategui M. [Routine examination of the mature newborn infant. Incidence of frequent "minor findings"]. *Wien Klin Wochenschr.* 1990;102:294-299
- Holm SA, Fattah R, Basset S, Nasser C. Developmental oral anomalies among schoolchildren in Gizan region, Saudi Arabia. *Community Dent Oral Epidemiol.* 1987;15:150-151
- Patterson GT, Ramasastry SS, Davis JU. Macroglossia and ankyloglossia in Beckwith-Wiedemann syndrome. *Oral Surg Oral Med Oral Pathol.* 1988;65:29-31
- Suri M, Kabra M, Verma IC. Blepharophimosis, telecanthus, microstomia, and unusual ear anomaly (Simosa syndrome) in an infant. *Am J Med Genet.* 1994;51:222-223
- Gorski SM, Adams KJ, Birch PH, Friedman JM, Goodfellow PJ. The gene responsible for X-linked cleft palate (CPX) in a British Columbia native kindred is localized between PGK1 and DXYS1. *Am J Hum Genet.* 1992;50:1129-1136
- Hughes-Benzie RM, Hunter AG, Allanson JE, Mackenzie AE. Simpson-Golabi-Behmel syndrome associated with renal dysplasia and embryonal tumor: localization of the gene to Xqcen-q21. *Am J Med Genet.* 1992;43:428-435
- Emmanouil-Nikoloussi E, Kerameos-Foroglou C. Congenital syndromes connected with tongue malformations. *Bull Assoc Anat (Nancy).* 1992;76:67-72
- Gunbay S, Zeytinoglu B, Ozkinay F, Ozkinay C, Oncag A. Orofaciodigital syndrome I: a case report. *J Clin Pediatr Dent.* 1996;20:329-332
- Martinot VL, Manouvrier S, Anastassov Y, Ribiere J, Pellerin PN. Orodigitofacial syndromes type I and II: clinical and surgical studies. *Cleft Palate Craniofac J.* 1994;31:401-408
- Defabianis P. Ankyloglossia and its influence on maxillary and mandibular development. (A seven year follow-up case report). *Funct Orthod.* 2000;17:25-33
- Wright JE. Tongue-tie. *J Paediatr Child Health.* 1995;31:276-278
- Sanchez-Ruiz I, Gonzalez Landa G, Perez Gonzalez V, et al. Section of the sublingual frenulum. Are the indications correct? [in Spanish]. *Cir Pediatr.* 1999;12:161-164
- Hasan N. Tongue tie as a cause of deformity of lower central incisor. *J Pediatr Surg.* 1973;8:985
- Williams WN, Waldron CM. Assessment of lingual function when ankyloglossia (tongue-tie) is suspected. *J Am Dent Assoc.* 1985;110:353-356
- Ewart NP. A lingual mucogingival problem associated with ankyloglossia: a case report. *N Z Dent J* 1990;86:16-17
- Nicholson WL. Tongue-tie (ankyloglossia) associated with breastfeeding problems. *J Hum Lact.* 1991;7:82-84
- Berg KL. Two cases of tongue-tie and breastfeeding. *J Hum Lact.* 1990;6:124-126
- Berg KL. Tongue-tie (ankyloglossia) and breastfeeding: a review. *J Hum Lact.* 1990;6:109-112
- Marmet C, Shell E, Marmet R. Neonatal frenotomy may be necessary to correct breastfeeding problems. *J Hum Lact.* 1990;6:117-121
- Fleiss PM, Burger M, Ramkumar H, Carrington P. Ankyloglossia: a cause of breastfeeding problems? *J Hum Lact.* 1990;6:128-129

22. Wilton JM. Sore nipples and slow weight gain related to a short frenulum. *J Hum Lact.* 1990;6:122–123
23. Hingley G. Ankyloglossia clipping and breast feeding. *J Hum Lact.* 1990;6:103
24. Notestine GE. The importance of the identification of ankyloglossia (short lingual frenulum) as a cause of breastfeeding problems. *J Hum Lact.* 1990;6:113–115
25. Velanovich V. The transverse-vertical frenuloplasty for ankyloglossia. *Mil Med.* 1994;159:714–715
26. Hazelbaker AK. *The Assessment Tool for Lingual Frenulum Function (ATLFF): Use in a Lactation Consultant Private Practice.* Pasadena, CA: Pacific Oaks College; 1993. Thesis
27. American Academy of Pediatrics, Work Group on Breastfeeding. Breastfeeding and the use of human milk. *Pediatrics.* 1997;100:1035–1039
28. Lawrence R. *Breastfeeding: A Guide for the Medical Profession.* 5th ed. St Louis, MO: Mosby-Year Book; 1999
29. Jain E. Tongue-tie: its impact on breastfeeding. *AARN News Lett.* 1995; 51:18
30. Huggins K. Ankyloglossia: one lactation consultant's personal experience. *J Hum Lact.* 1990;6:123–124
31. Messner AH, Lalakea ML, Aby J, Macmahon J, Bair E. Ankyloglossia: incidence and associated feeding difficulties. *Arch Otolaryngol Head Neck Surg.* 2000;126:36–39
32. Kotlow LA. Ankyloglossia (tongue-tie): a diagnostic and treatment quandary. *Quintessence Int.* 1999;30:259–262